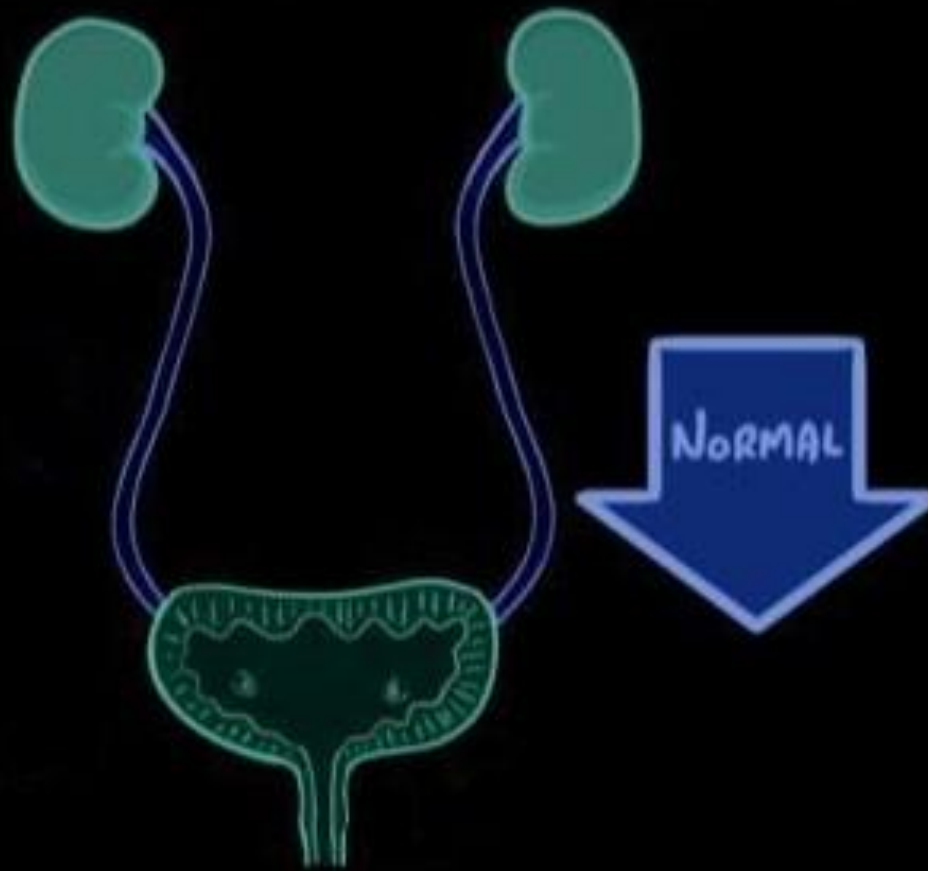
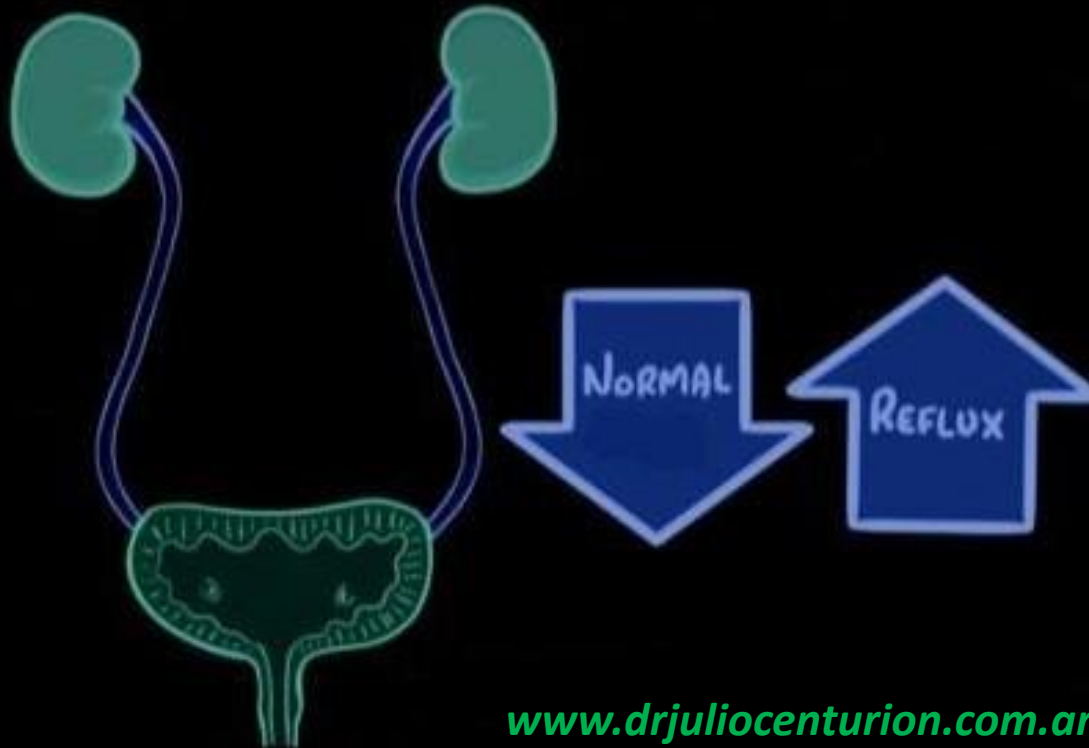


www.drjuliocenturion.com.ar

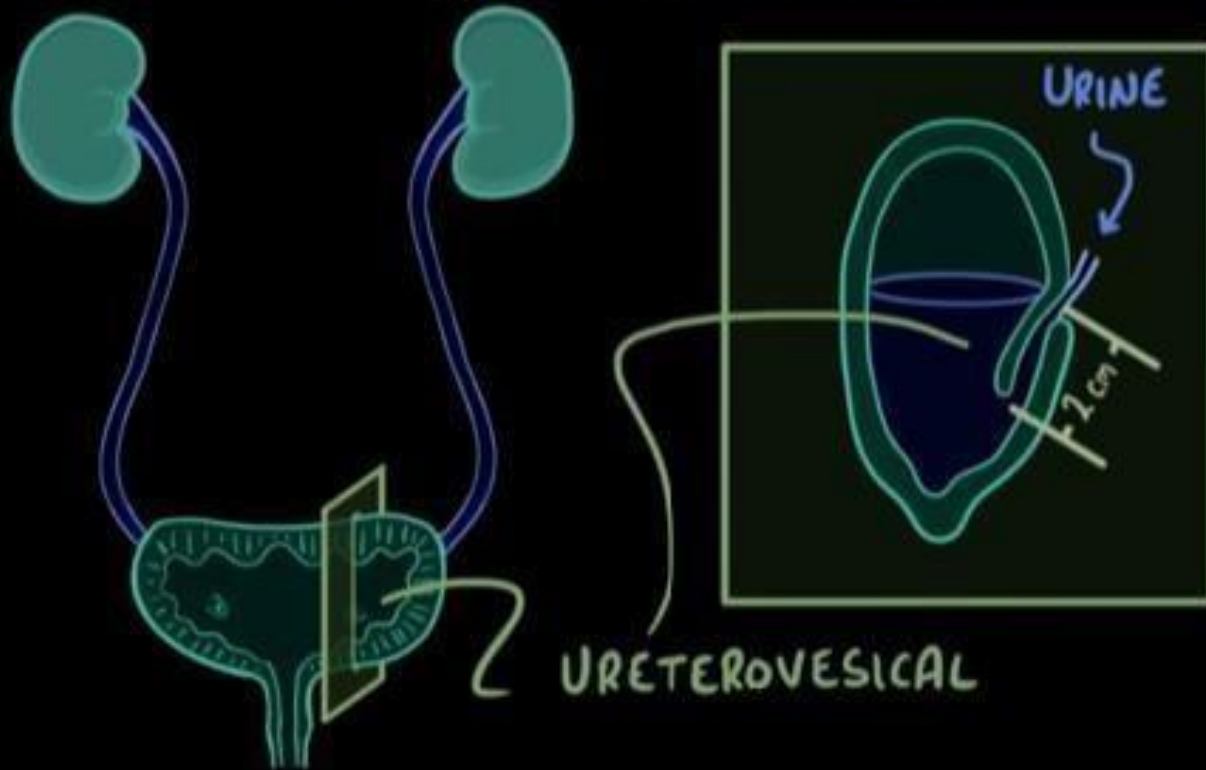


VESICoureTERAL REFLEX

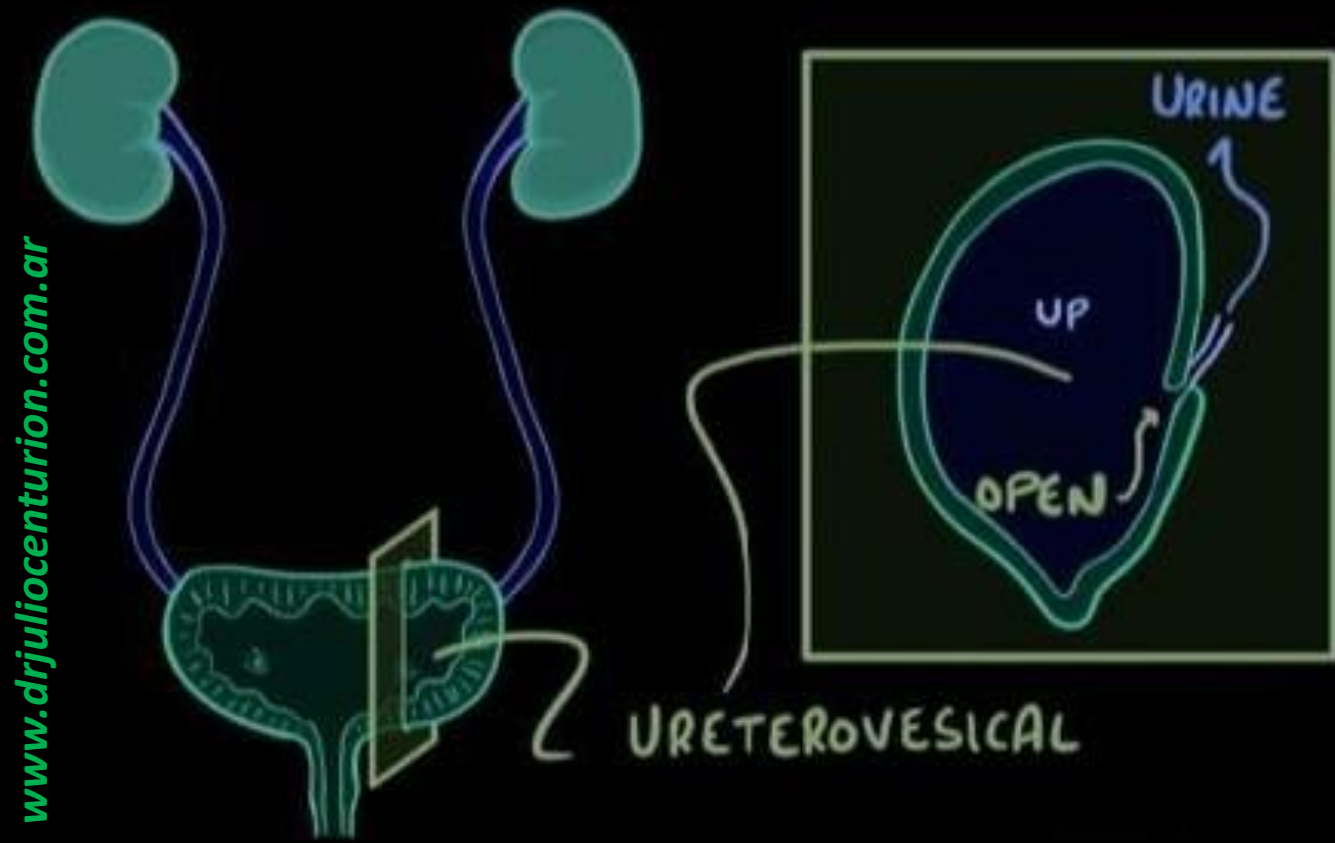


PRIMARY VESICoureTERAL REFLUX

www.drjuliocenturion.com.ar



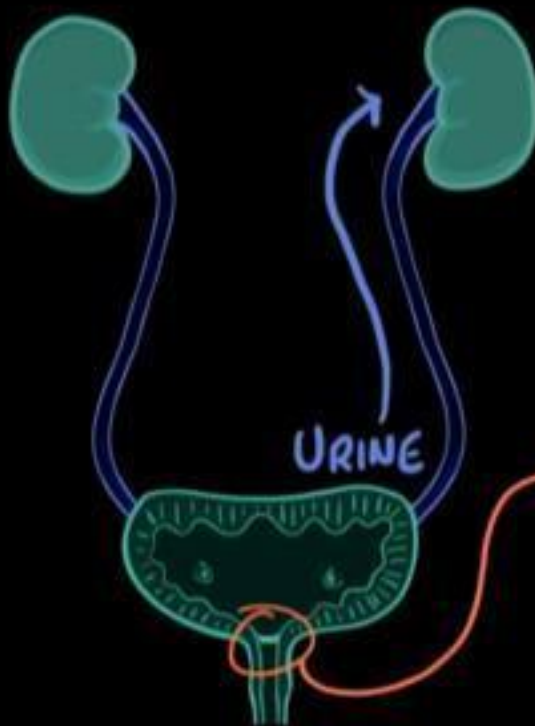
PRIMARY VESICoureTERAL REFLUX



www.drjulioenturion.com.ar

SECONDARY VESICoureTERAL REFLUX

OBSTRUCTION \rightarrow increase in pressure



most common

* URINARY TRACT INFECTIONS

\rightarrow URETERS SWELL & CLOSE

* POSTERIOR URETHRAL VALVE DISORDER

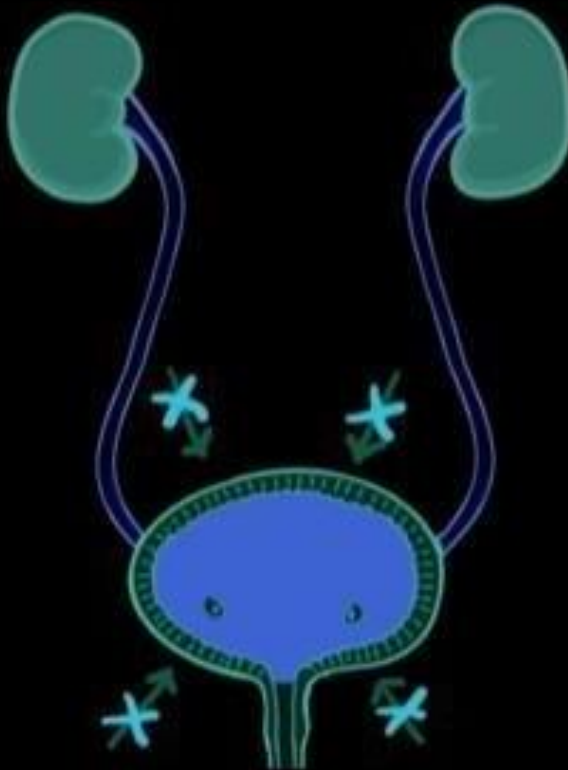
- DIAGNOSED in BABIES

MEMBRANE forms over URETHRA

www.drjuliocenturion.com.ar

SECONDARY VESICoureTERAL REFLUX

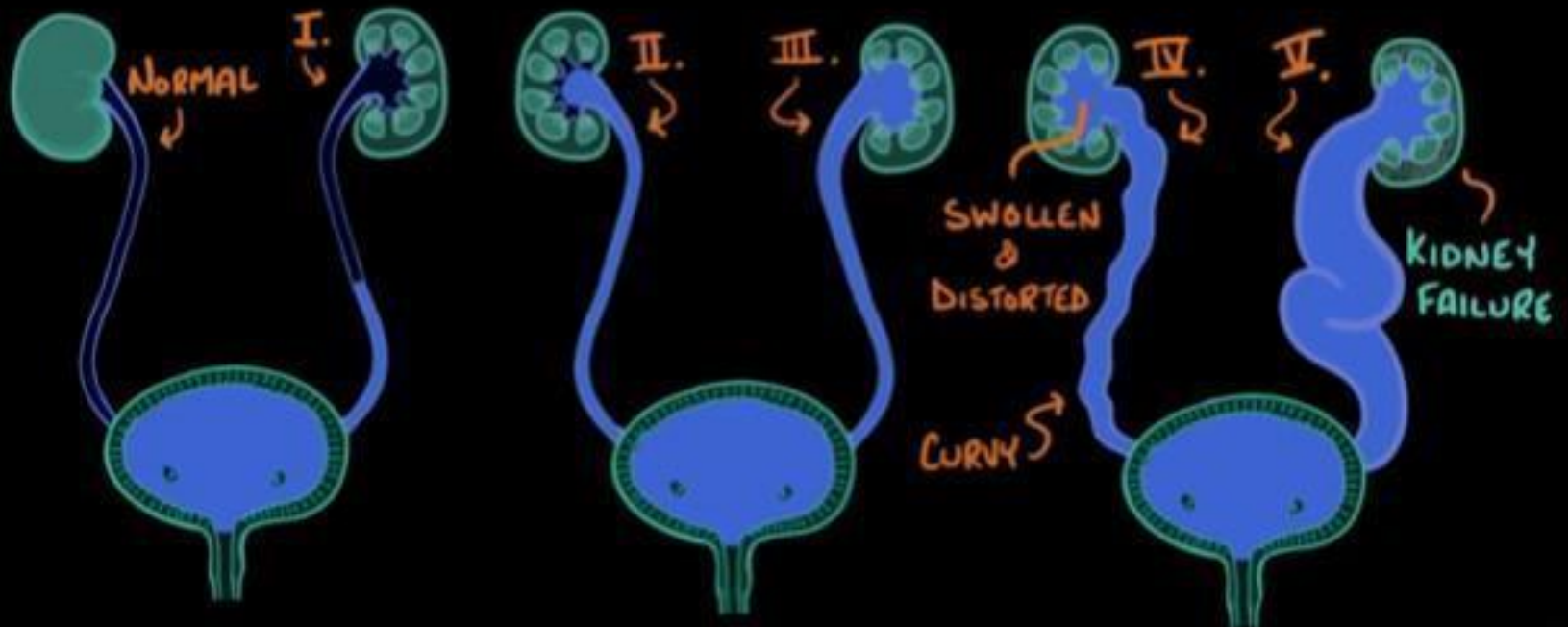
OBSTRUCTION \rightarrow increase in pressure



* FLACCID NEUROGENIC BLADDER

GRADES of VESICoureTERAL REFLUX

www.drjuliocenturion.com.ar



SYMPTOMS

MILDER CASES: NO SYMPTOMS

SEVERE CASES: URINE LINGERS

↳ CAUSING INFECTION

↳ PYELONEPHRITIS
(INFLAMMATION OF KIDNEYS)

↳ RENAL SCARRING



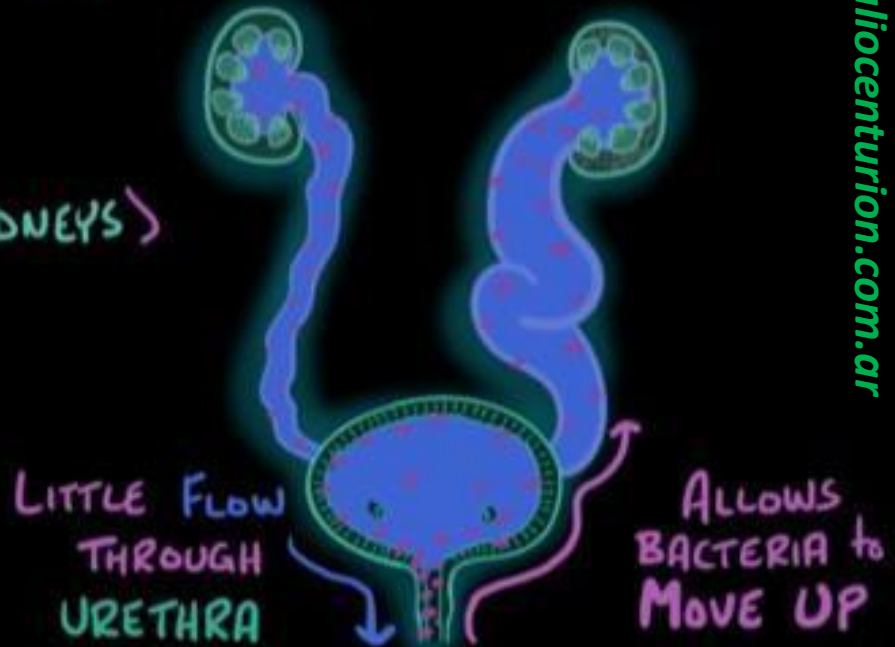
REDUCES BLOOD FLOW TO KIDNEYS



INCREASES BLOOD PRESSURE

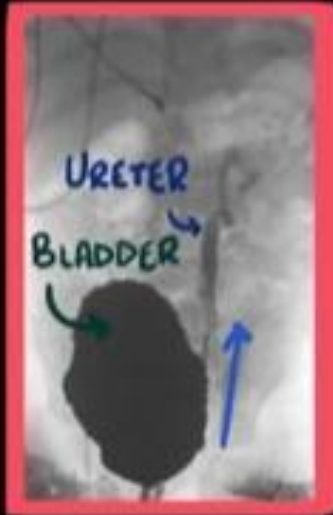

HYPERTENSION



DIAGNOSIS

www.drjulioenturion.com.ar



- * ABDOMINAL ULTRASOUND
 - ↳ DETECTS BLOCKAGES & SWELLING
- * VOIDING CYSTOURETHROGRAM (VCUG)
 - ↳ SHOWS HOW URINE MOVES THROUGH the URETEROVESICAL JUNCTION
- * RADIONUCLIDE CYSTOGRAM
 - ↳ TRACER INJECTED into BLOOD VESSEL
 - ↳ SCANNER DETECTS TRACER as it MOVES:
BLOOD → KIDNEY → URETERS → BLADDER

TREATMENT

DEPENDS on AGE
& SEVERITY

* as CHILD GROWS URETERS get LONGER



VALVE FUNCTION IMPROVES



PRIMARY VESICoureTERAL REFLEX
SOMETIMES IMPROVES or DISAPPEARS

* SURGERY

↳ REMOVE a BLOCKAGE

↳ REPAIR a VALVE

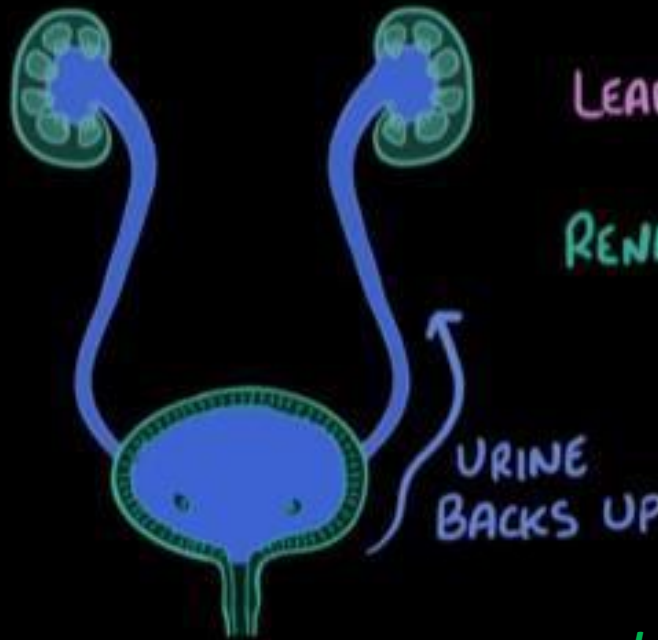
www.drjuliocenturion.com.ar

VESICoureTERAL REFLUX

PRESSURE in OUTFLOW INCREASES

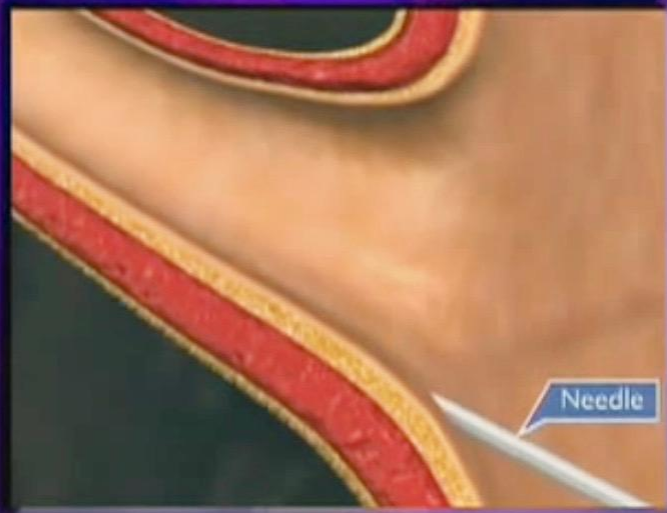PRIMARY VUR
↳ SHORT URETERS

SECONDARY VUR
↳ BLOCKAGE

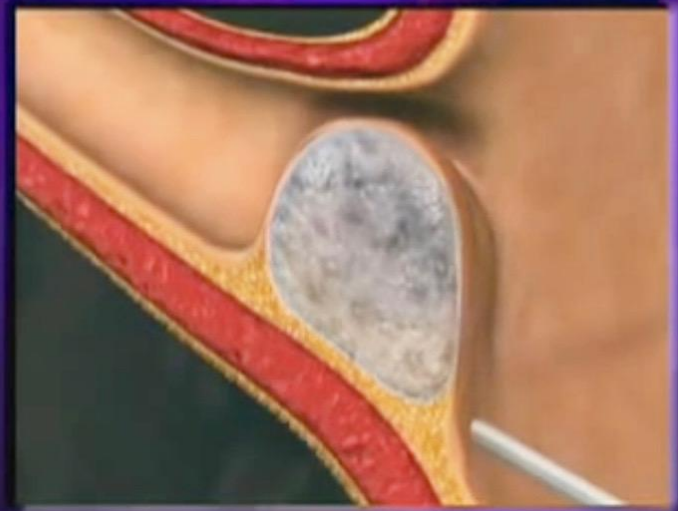

LEADS to INFECTION
↓
RENAL INFLAMMATION
&
SCARRING

Endoscopic Injection



Endoscopic Injection



www.drjuliocenturion.com.ar