

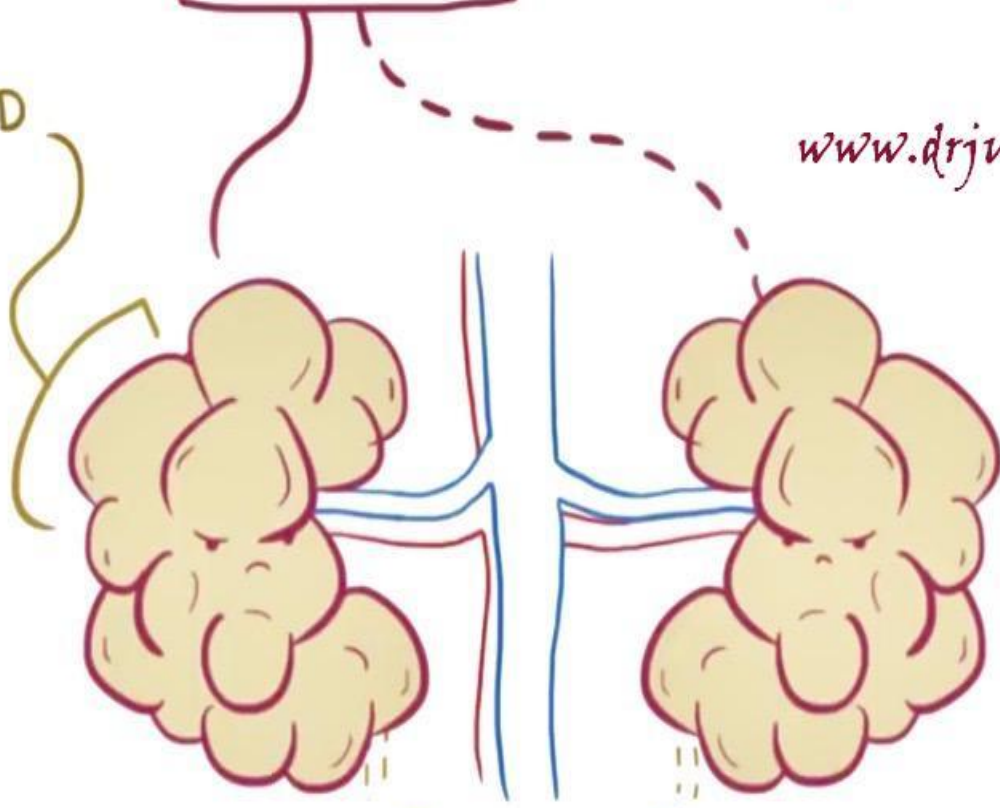
BAD FORMATION

MULTICYSTIC DYSPLASTIC

KIDNEY (MCDK)

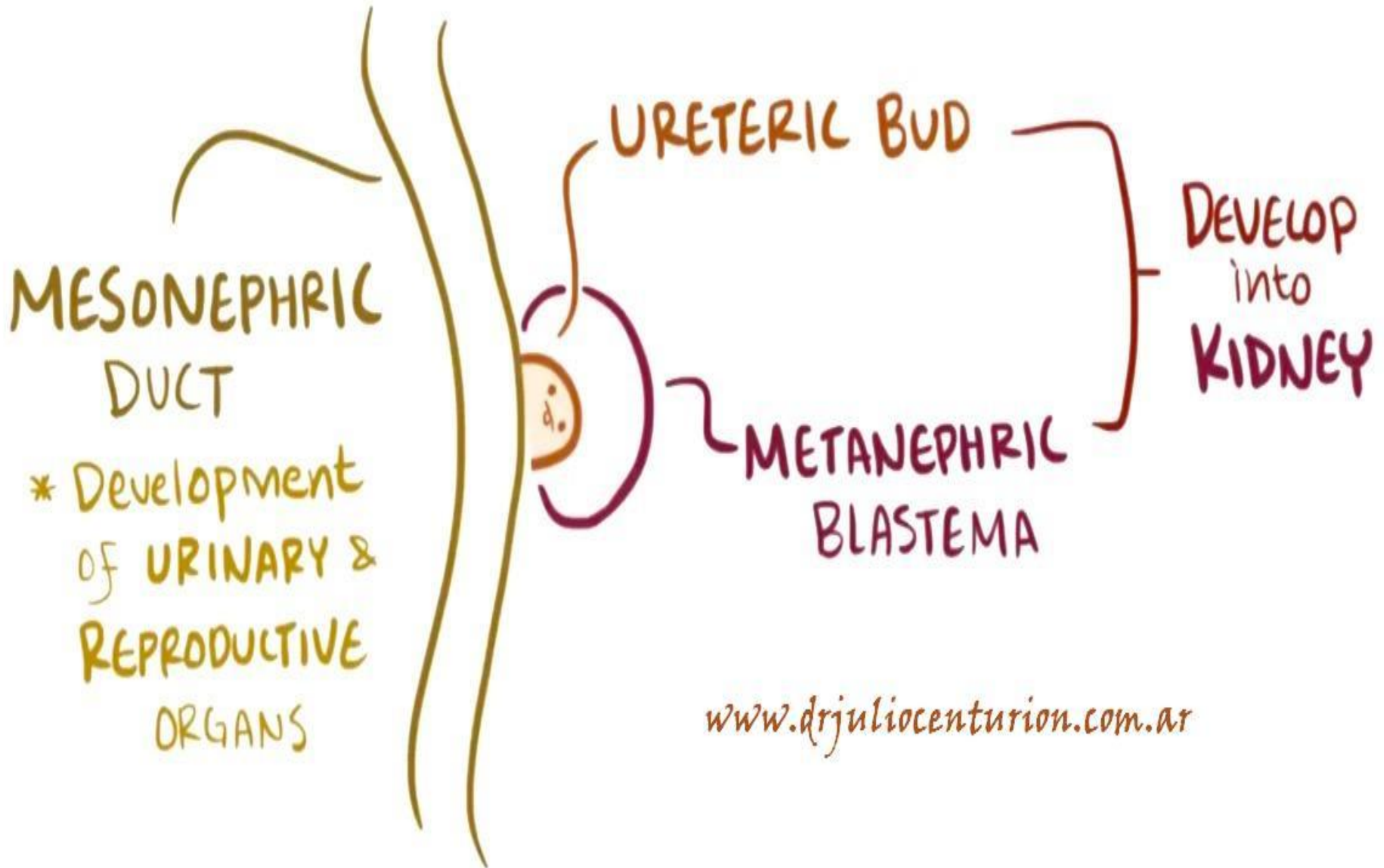
CYST
FLUID-FILLED
SAC

www.drjuliocenturion.com.ar

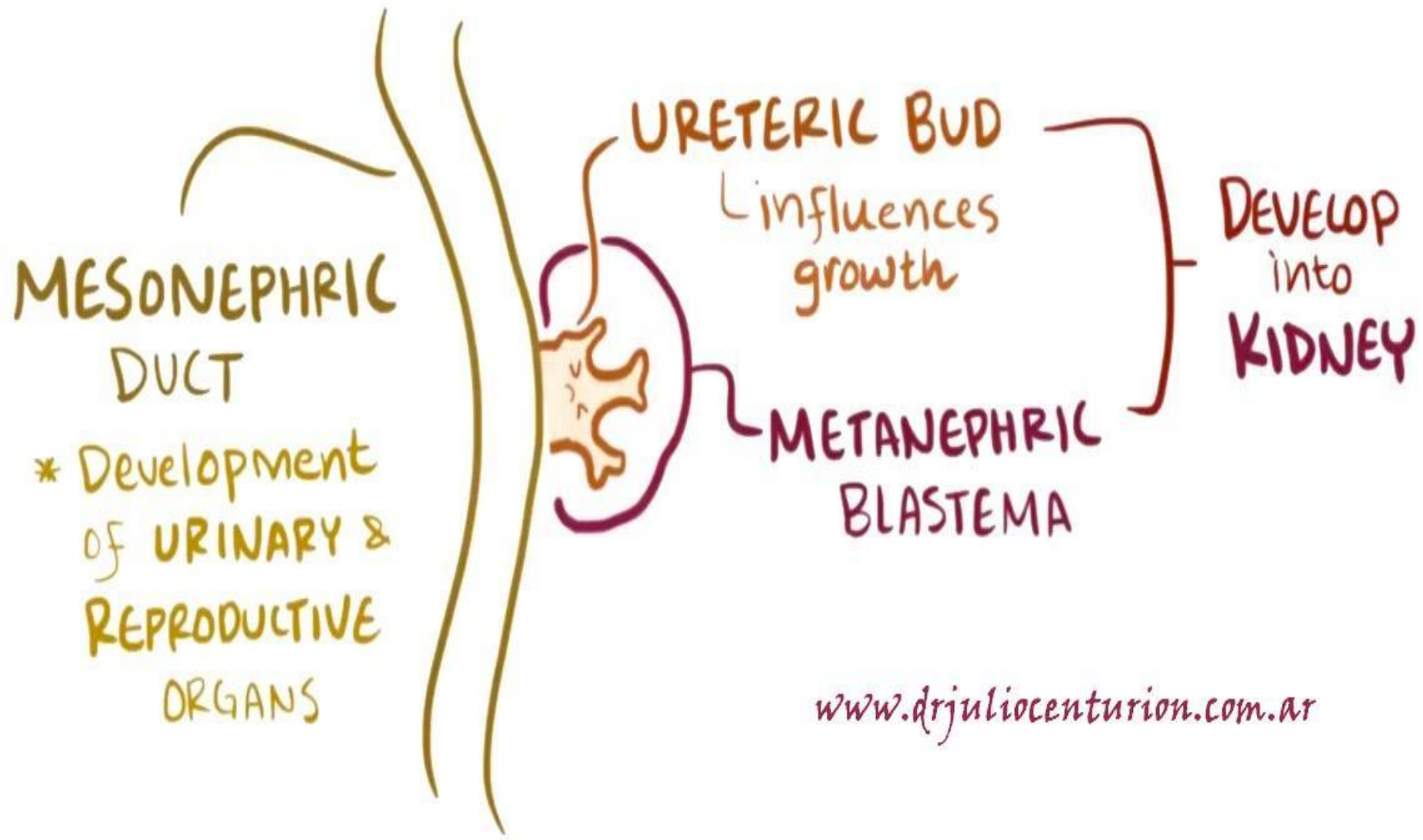


URINE DOESN'T DRAIN

WEEK 5



WEEK 7

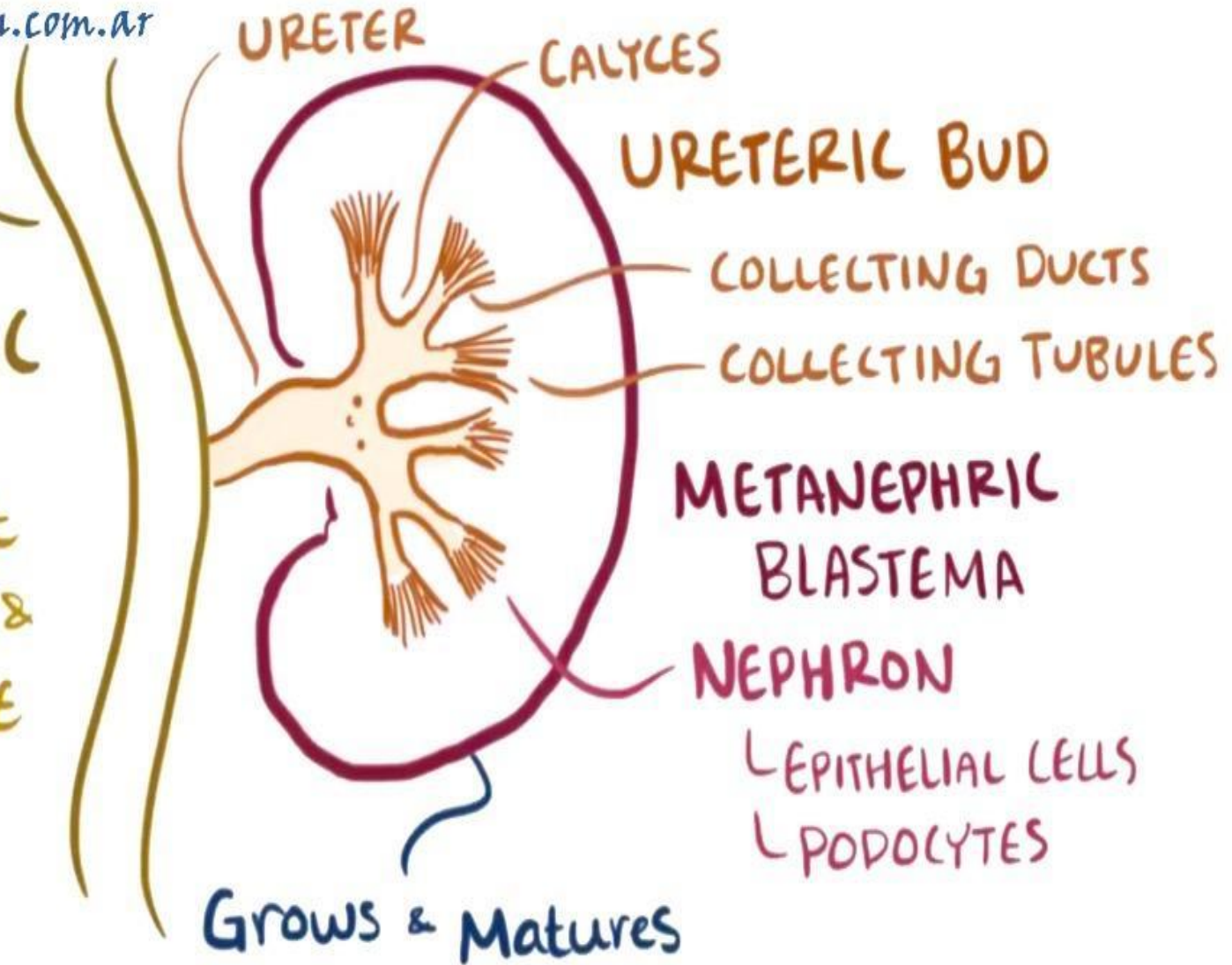


WEEK 28 - INFANCY

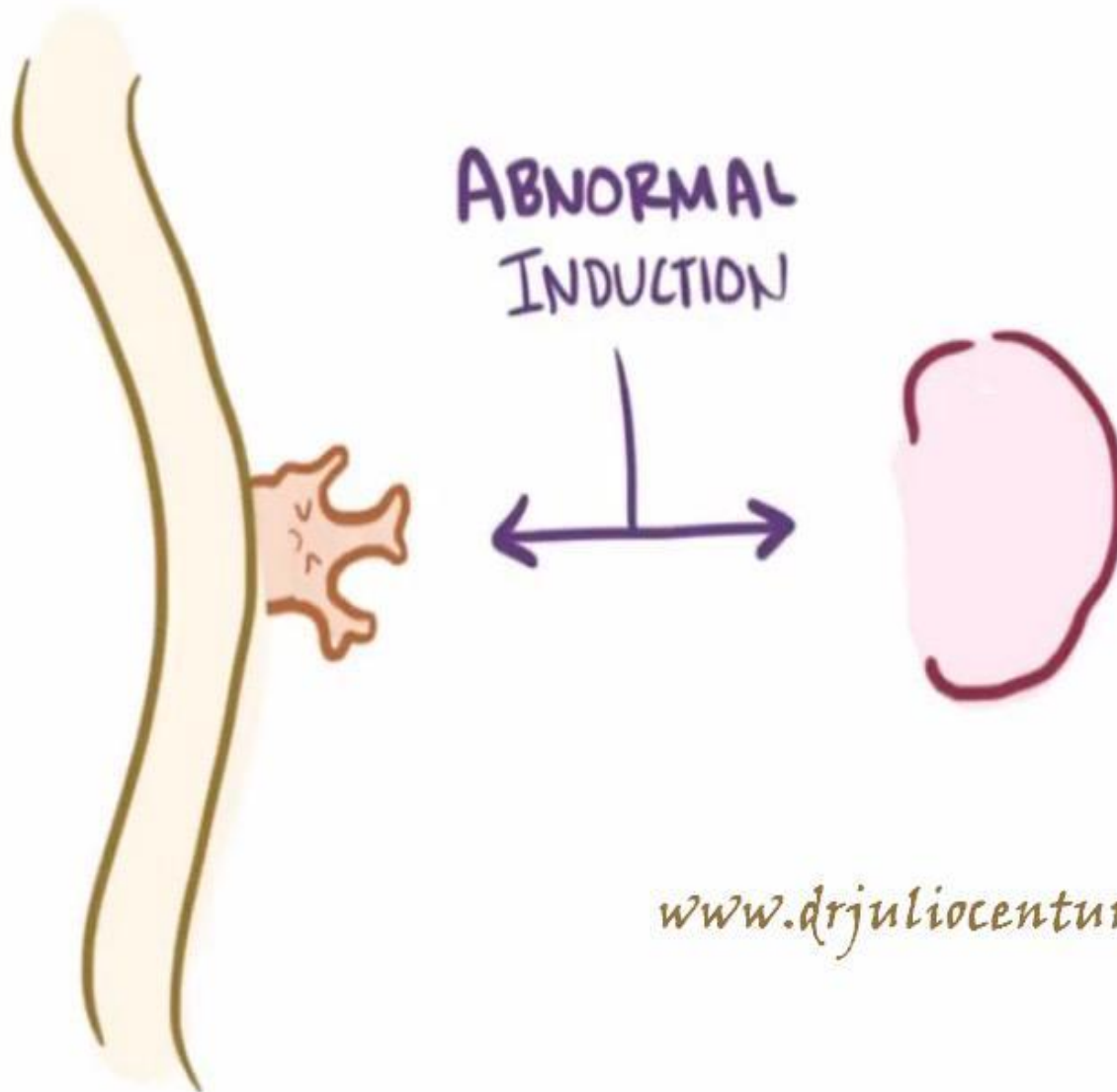
www.drjuliocenturion.com.ar

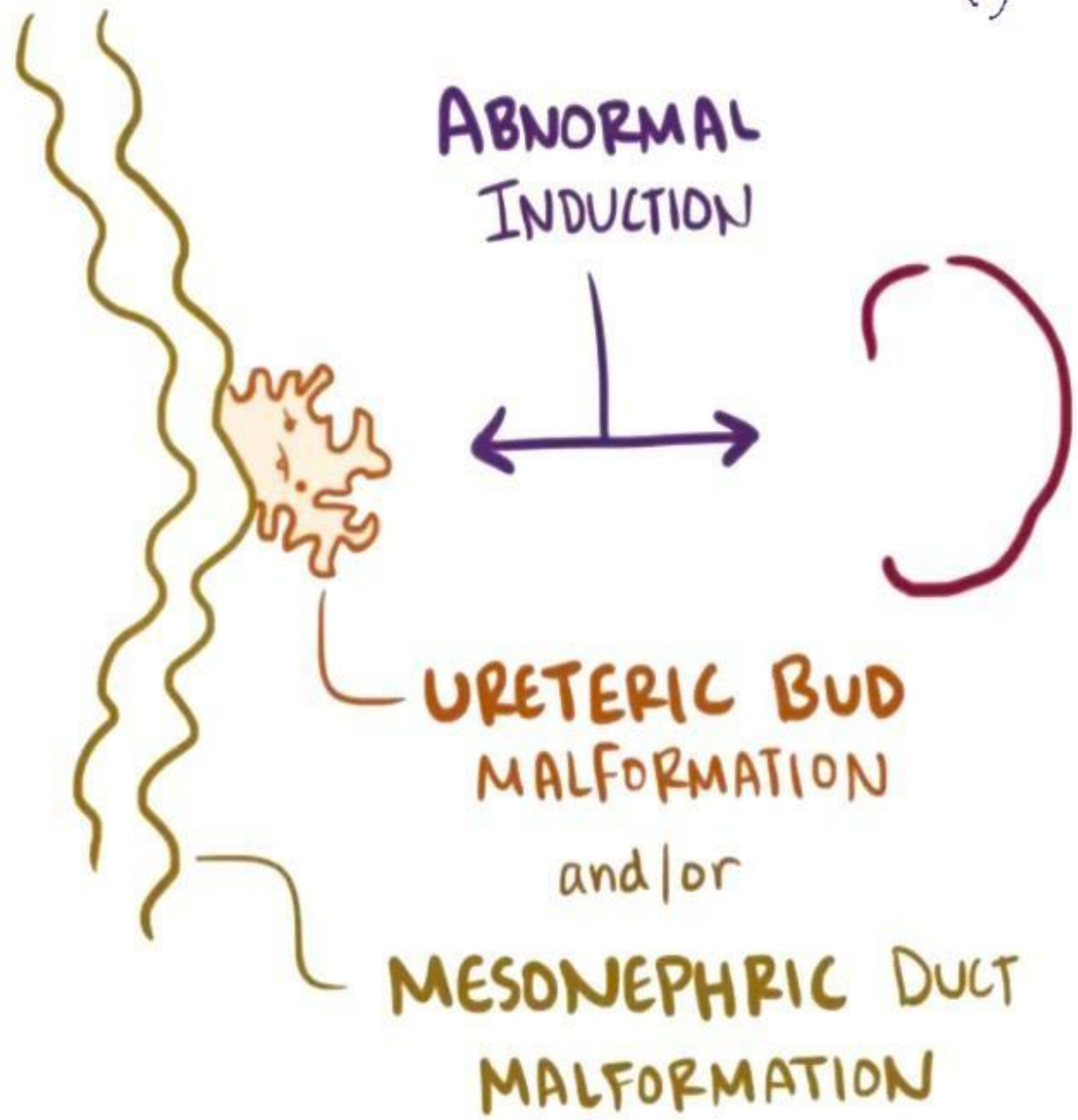
MESONEPHRIC
DUCT

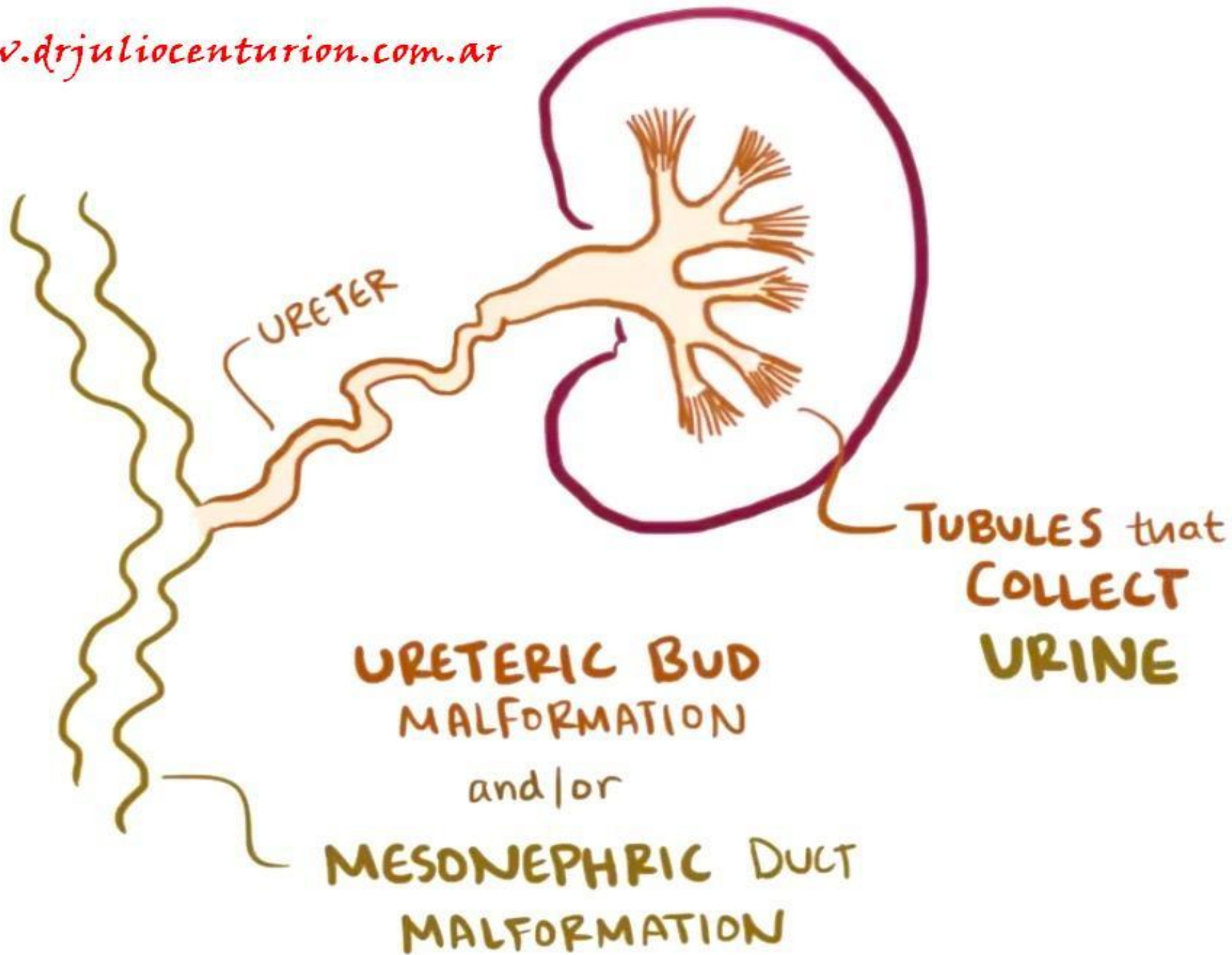
* Development
of URINARY &
REPRODUCTIVE
ORGANS



Grows & Matures



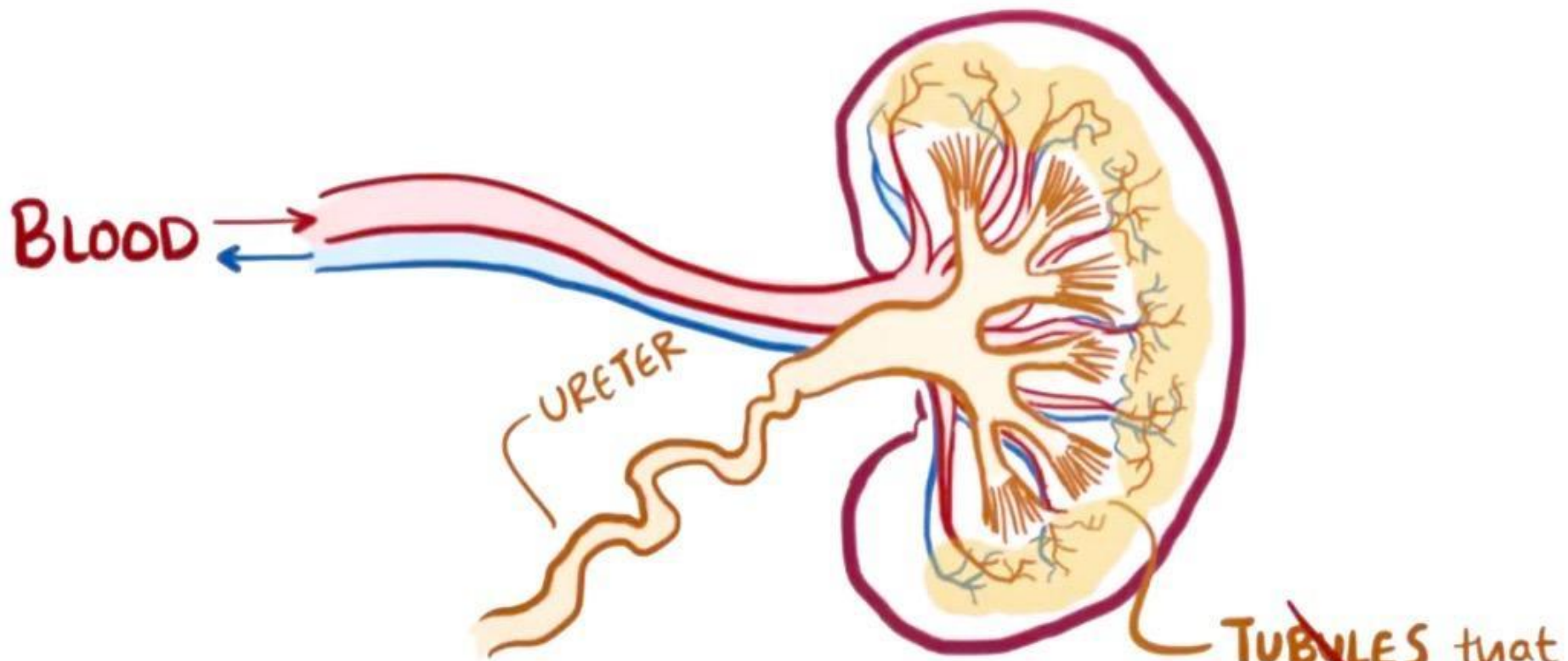




URETER

TUBULES that
COLLECT
URINE

URETERIC BUD
MALFORMATION
and/or
MESONEPHRIC DUCT
MALFORMATION



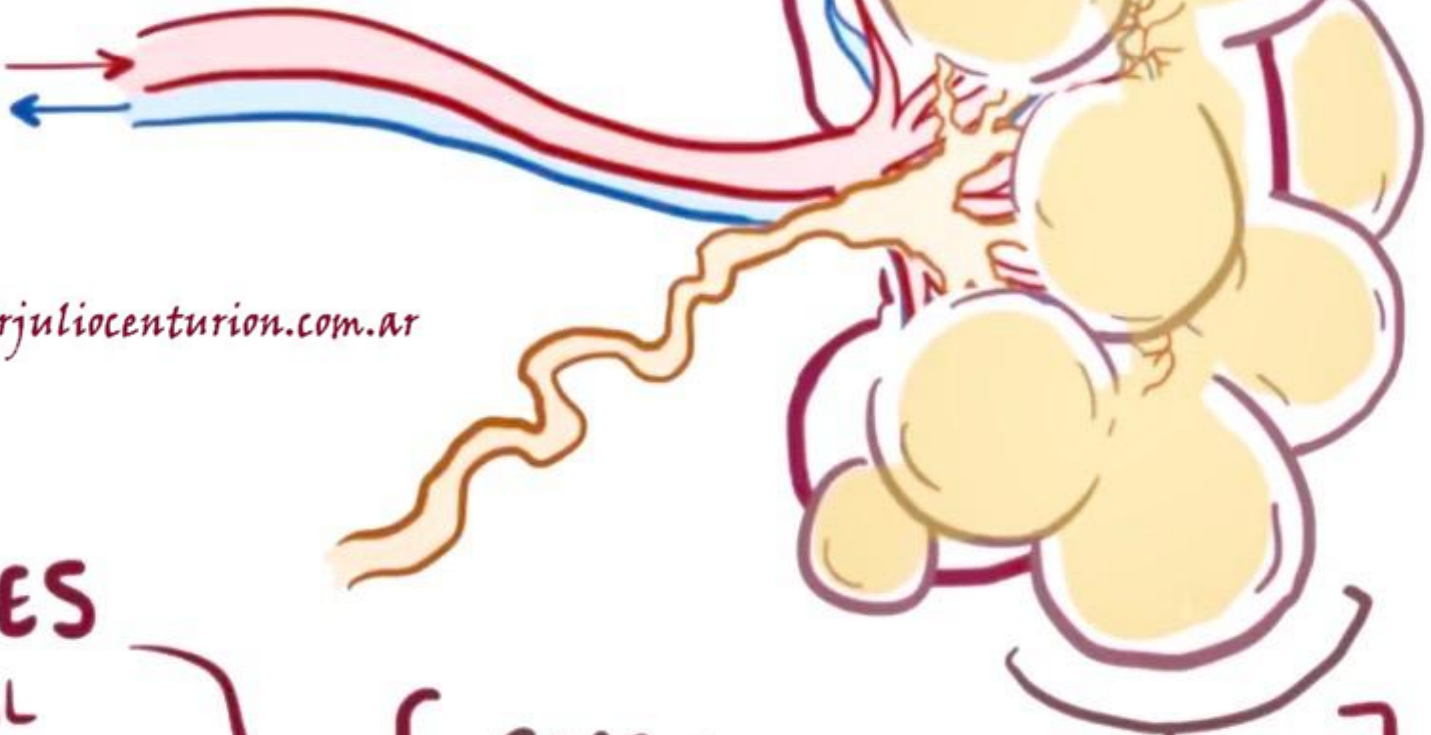www.drjuliocenturion.com.ar

**URETERIC BUD
MALFORMATION**

and/or

**MESONEPHRIC DUCT
MALFORMATION**

BLOOD

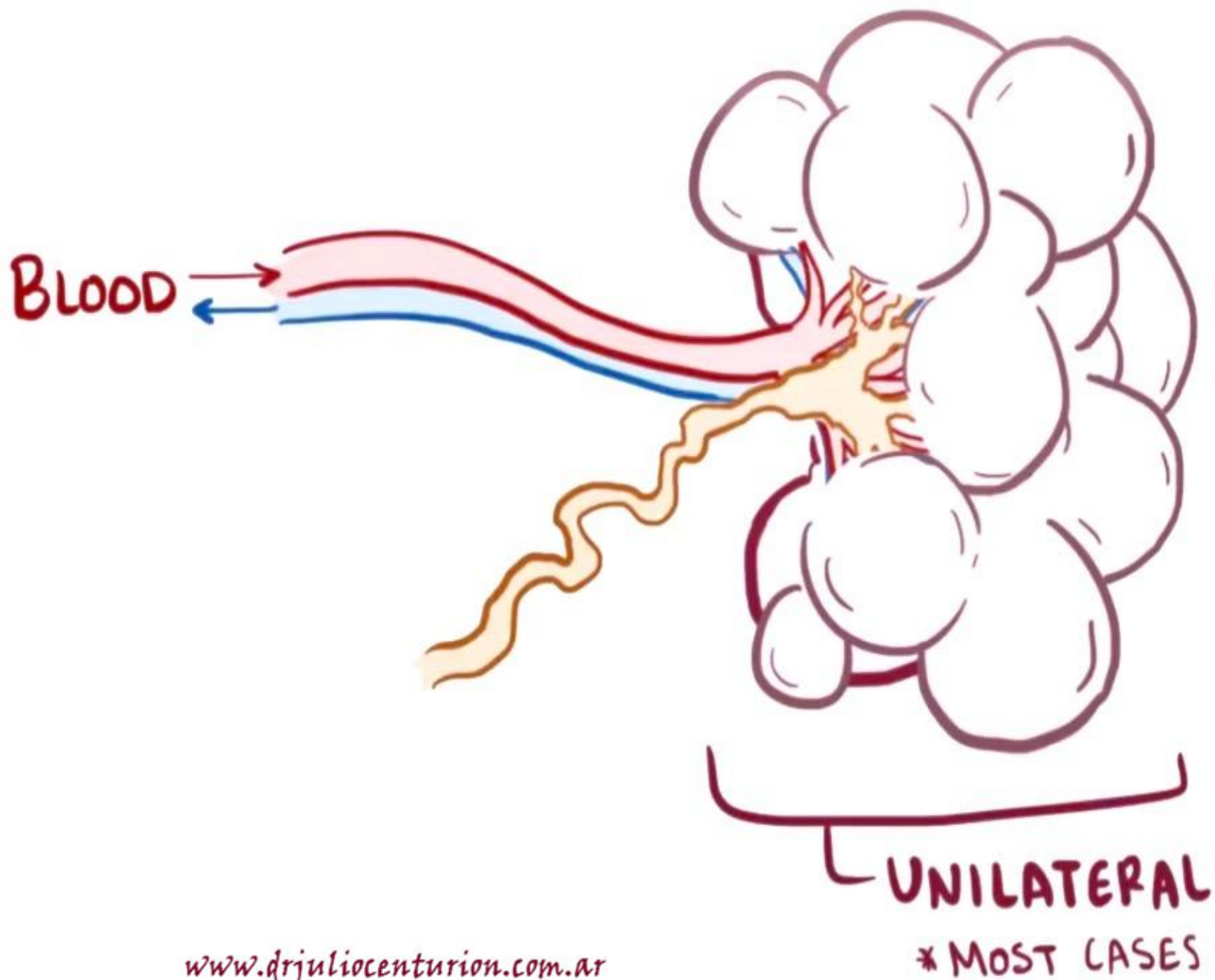


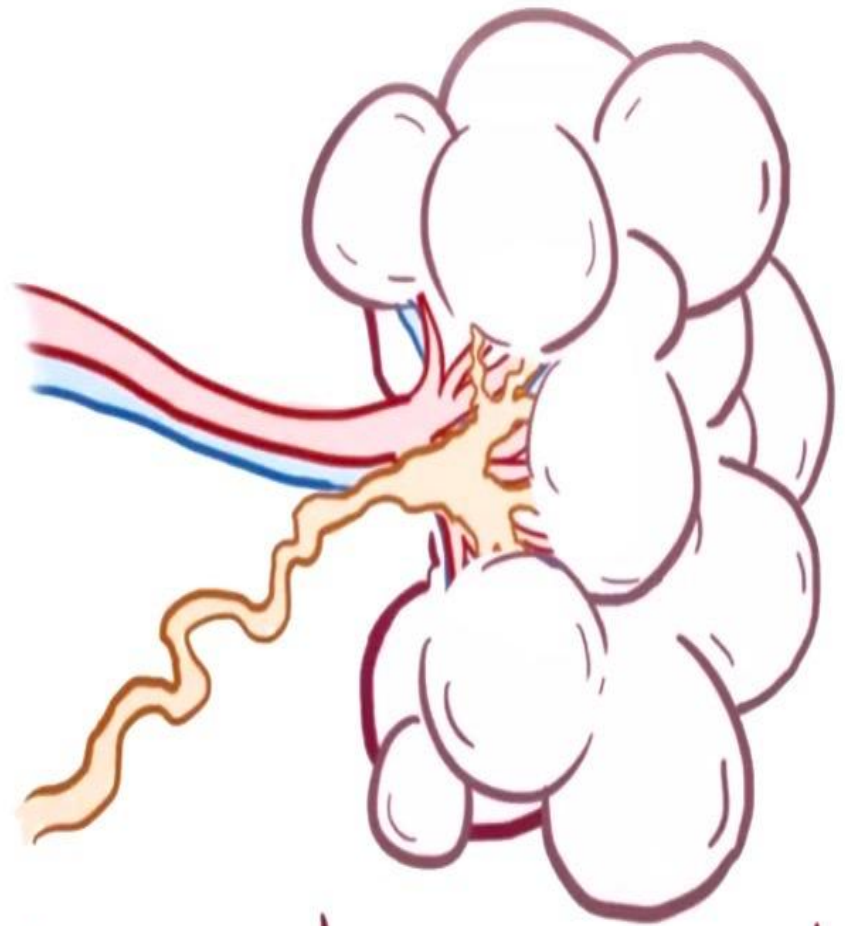
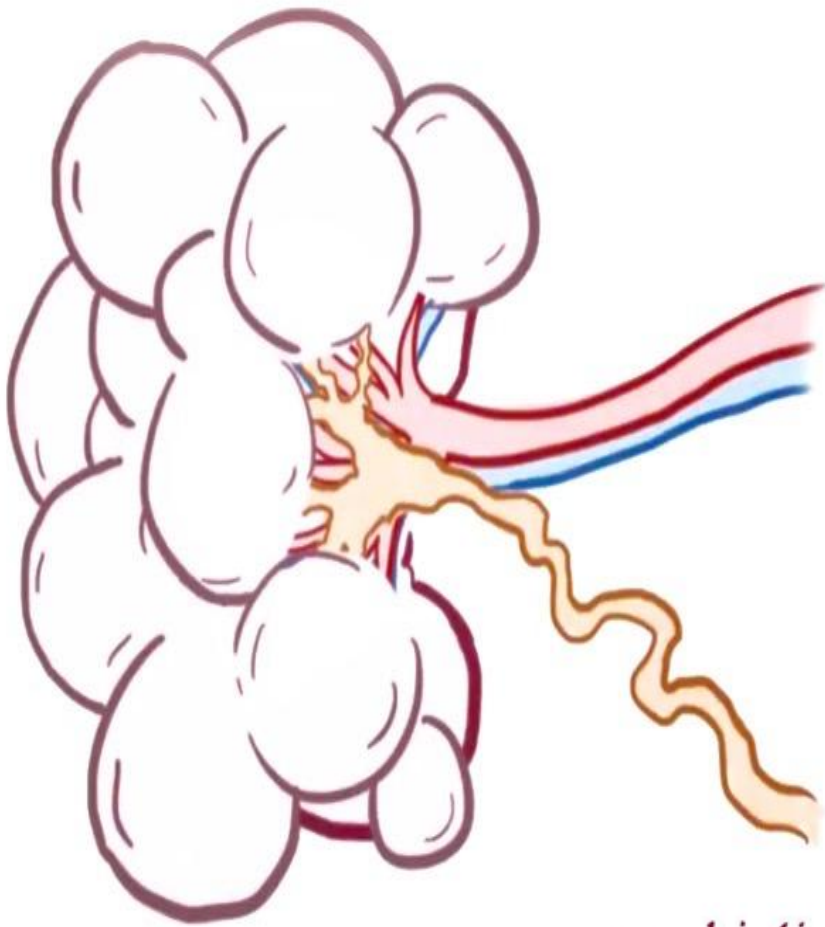
www.drjuliocenturion.com.ar

**REPLACES
NORMAL
TISSUE**

CYST

↳ abnormal connective
tissue (e.g. **CARTILAGE**)





www.drjuliocenturion.com.ar

BILATERAL

UNILATERAL
* MOST CASES

MCDK

* SPORADIC *



NO CLEAR
INHERITANCE
PATTERN

VS.

POLYCYSTIC KIDNEY DISEASE

* FAMILIAL *



INHERITED

↳ Autosomal
dominant

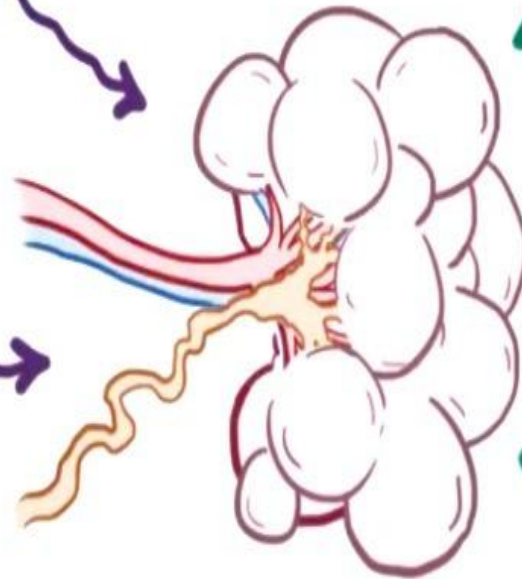
MCDK

GENETIC SYNDROMES

↳ Papillorenal Syndrome

GENES

↳ EYA1
↳ SIX1
↳ PAX2



PRESCRIPTION DRUGS

for
MATERNAL HYPERTENSION
(ACE Inhibitors)

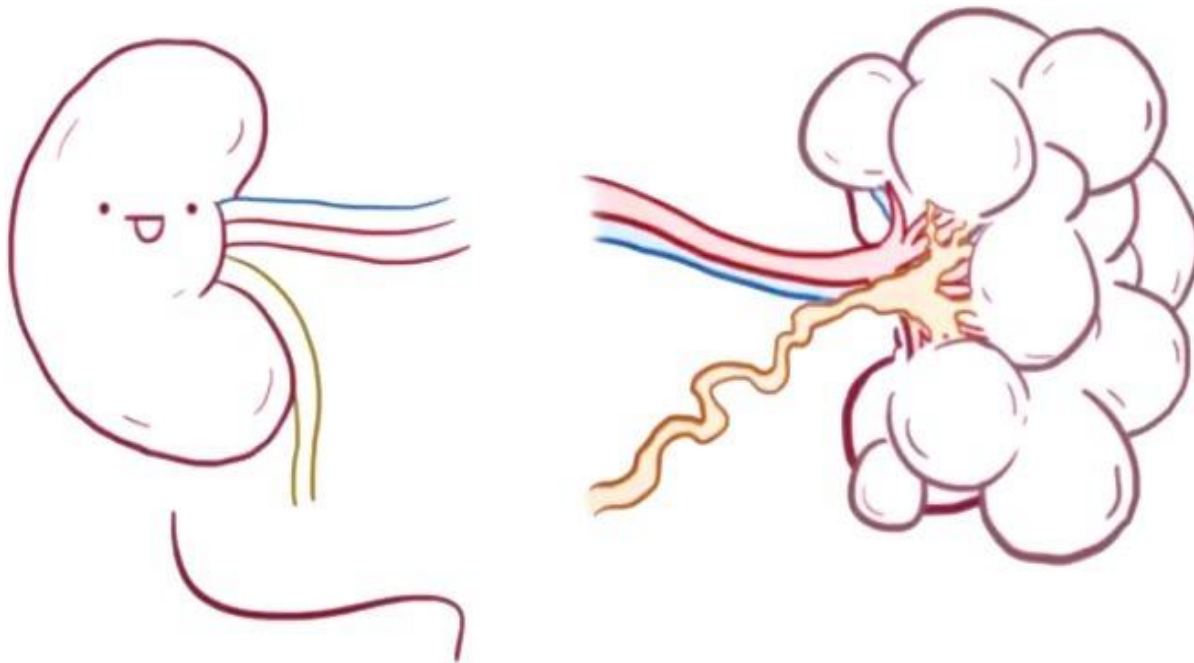
ILLICIT DRUGS

* COCAINE *

www.drjuliocenturion.com.ar

MCDK

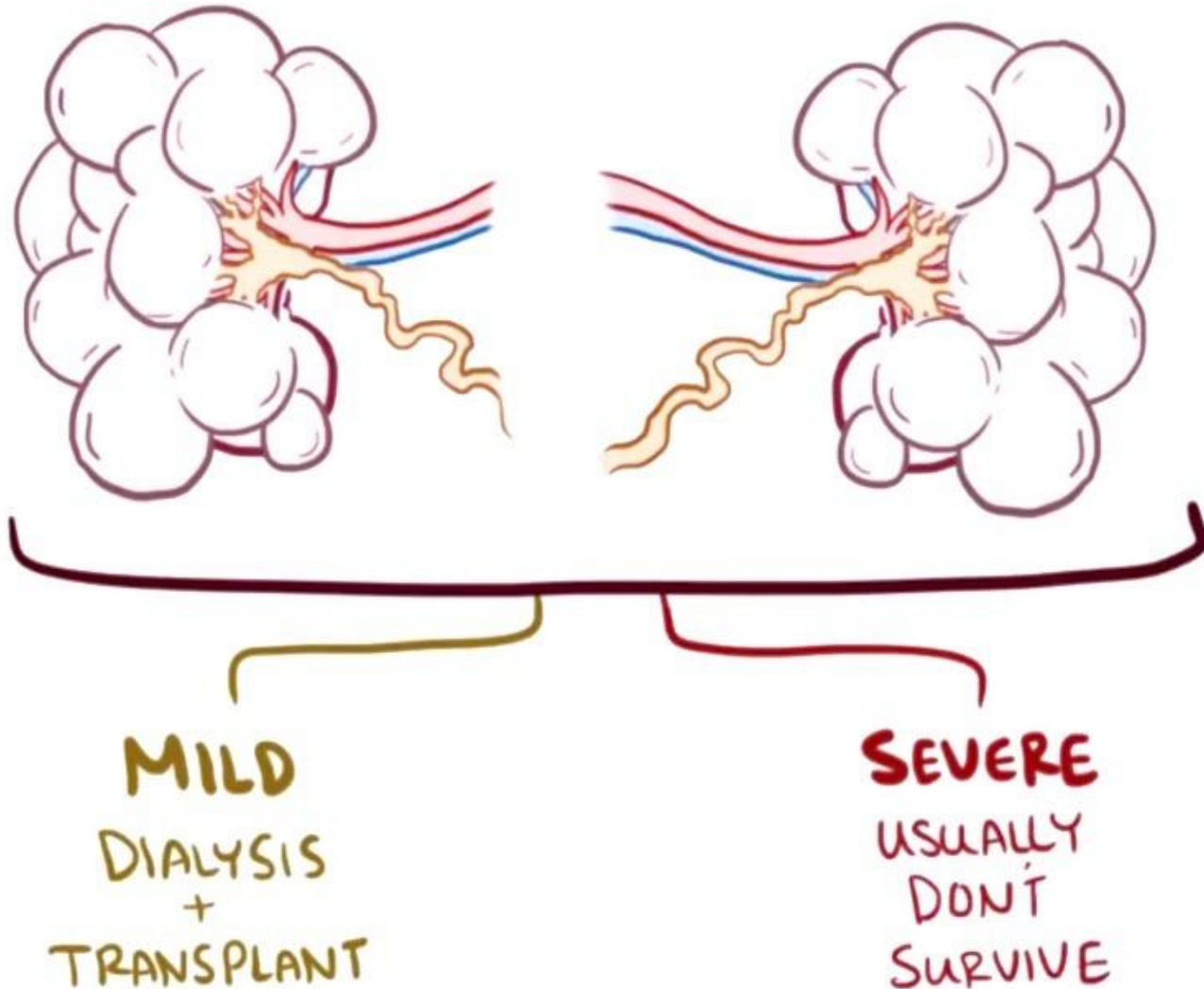
www.drjuliocenturion.com.ar



NORMAL

↳ may be able to
preserve function

MCDK



MULTICYSTIC DYSPLASTIC KIDNEY

MCDK

~ NON-INHERITED
CONGENITAL DISEASE

